

Esthetic Rehabilitation in a Patient with Mesiodens

Saumyendra V. Singh¹, Kapil Loomba², Promila Verma³, Rhythm Bains², Vivek K Bains⁴
and Gunjan Srivastava¹

ABSTRACT

Aim: This paper documents the treatment of a patient with mesiodens and malaligned teeth, having limited time and financial constraints for comprehensive management of the case.

Summary: Esthetic reconstruction of an adult patient presenting with mesiodens and malaligned teeth presents a complex problem which is increased if orthodontic management is not feasible because of constraints of time, economics and age, and when immediate results are needed of the hour, and are pressing and demanding. This paper presents a clinical report of such a patient, where satisfactory treatment outcome was accomplished after logical, diagnostic approach, that resulted in appropriate treatment plan involving experts from various disciplines.

Keywords: Anterior esthetic, Malalignment, Mesiodens.

Developmental anomalies are among the important factors accountable for functional, esthetic and occlusal discrepancy, and amongst these supernumerary dentition have a significant place. Supernumerary teeth occur more frequently in permanent (2.1%) as compared to deciduous dentition (0.8%) and twice more common in males than females² with overall prevalence ranging from 0.15% to 3.9% and are five times more common in maxilla than mandible.^{3,4} In patients with cleidocranial dysplasia, frequencies of supernumerary ranged from 22% in maxillary anterior region to 5% in molar region.²

Supernumerary teeth in permanent dentition occur more frequently in anterior region as conical supernumerary, mesiodens, than any other part of either dental arch,^{2,5,6} and is considered most frequent supernumerary tooth with an overall prevalence of 0.15% to 1.9%.⁷ Data suggests that maxillary anterior supernumerary teeth occurred less commonly in females than males.^{6,8-11} Mesiodens are reported to occur slightly more on left side of midline than on right side,^{6,11} but others observed it slightly more on the right side of midline.^{12,13} Most common type mesiodens are unerupted that are usually located palatally and results in formation of mid-line diastema.¹⁴ Mesiodens may present itself as single tooth, in pairs or multiple (mesiodentes) supernumerary teeth.¹⁵ This paper documents the treatment of a patient with mesiodens and malaligned teeth, having limited time and financial constraints for comprehensive management of the case.

INTRODUCTION

Now-a-days, dentistry faces increased challenges especially due to awareness of esthetics. Thus dentists need to be more organized and systematic, with the objective of maintaining the health of the patient and teeth. General dental practitioners must have a thorough understanding of roles of various disciplines with most conservative and biologically sound interdisciplinary management to produce an esthetic renovation.¹

CLINICAL REPORT

A systemically healthy, non-smoker, 30 year old male farmer from low socioeconomic status came to the institution for improvement of facial appearance few months prior to his marriage. He reported a recent history of trauma to his upper left front incisor and pain which was relieved after taking analgesics. The dental history indicated that some lower posterior teeth had been lost about a year back due to poor periodontal health.

Extra-oral examination showed a straight profile, competent lips and a normal smile line with no muscle or TMJ abnormalities. Intra-oral examination revealed below average

¹Department of Prosthodontics, ³Conservative Dentistry & Endodontics, Faculty of Dental Sciences, Chhatrapati Shahuji Maharaj Medical University, Lucknow, ²Conservative Dentistry & Endodontics, ⁴Periodontology, Saraswati Dental College & Hospital, Lucknow (UP), India.

Address for Correspondence:

Dr Kapil Loomba,
3 Park Lane,
Lucknow (UP)-226001, India.
Contact No: +919839012241, E-mail: kl_loomba@yahoo.co.in
Date of Submission : 08-06-2011
Reviews Completed : 24-06-2011
Date of Acceptance : 28-06-2011

oral hygiene, soft tissues of the lips, cheeks, tongue, oral mucosa, and pharynx were normal. The saliva was thin and serous and the patient did not have any addictive habits. Maxillary right canine (13) was in severe labioversion and out of arch form, whereas the left maxillary canine (23) was in slight labioversion. The maxillary left (12) and right lateral (22) incisors were lingually placed and in crossbite, while the maxillary right central incisor (11) was lingually placed, rotated and in crossbite by about 4 mm. The maxillary left central incisor (21) was bulky and massive in mesio-distal dimension (13 mm) and appeared to be a fusion of the central incisor and a mesiodens (Fig. 1 and 2). Further exploration revealed that the tooth was fractured, and removal of the mobile mesio-lingual chunk leads to less than one-third coronal structure remaining. Another mesiodens was present between teeth 11 and 21. The mandibular arch was partially dentate with teeth 37, 36, 46, 47 and 48 missing. Periodontal examination revealed presence of shallow to moderately deep pockets in relation to all the teeth. The patient was unable to move his mandible in anterior guidance because of the locking effect of his lateral incisors.

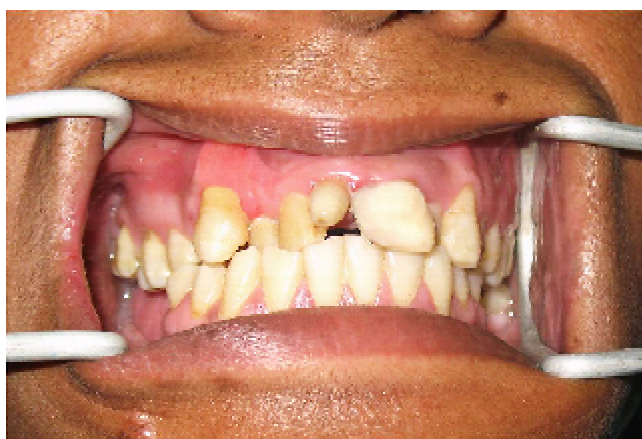

Figure 1: Preoperative frontal view.

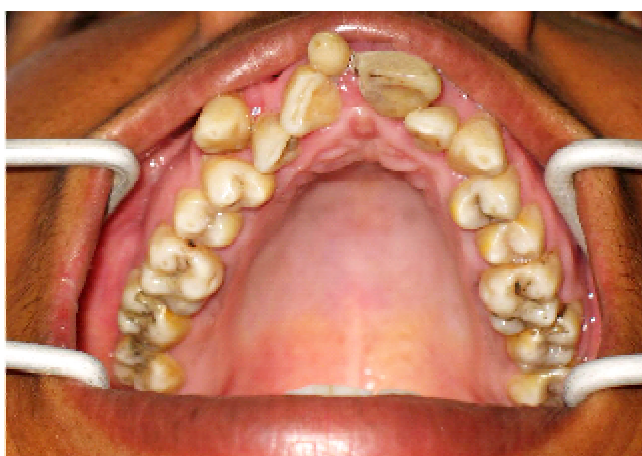


Figure 2: Preoperative occlusal view

To ascertain diagnosis, orthopantomograph and Intraoral periapical (IOPA) radiographs were taken and diagnostic casts were prepared. Vitality test was performed on 13, 12, 11, 21, 22 and 23 and results showed non-vital 21 but all other teeth were vital. Based on clinical findings, radiographic examination and vitality tests, patient was diagnosed as having generalised chronic periodontitis associated with Class I Type 1 malocclusion, mesiodens and non-vital, probably fused central incisor. Within the limitation of the situation of the case presented, ideal treatment planning that includes orthodontic tooth movement was not feasible, and every effort was made to improve the esthetics judiciously and ethically.

Non-surgical periodontal therapy that included thorough scaling and root planing followed by irrigation of the periodontal pockets with 0.2% chlorhexidine was done and oral hygiene instructions were given to the patient, ensuring that the patient was following strict oral hygiene regimen at all further appointments. Two sets of study casts were made using rubber base impression material and improved dental stone. The maxillary cast of one set was articulated on Whipmix articulator using an ear piece facebow and the mandibular cast was articulated using a wax occlusal centric relation record. These articulated casts were used for initial diagnosis, treatment planning and to record and replicate existing occlusal relationship. The other maxillary cast was used for mock diagnostic preparation and wax up, post which a decision was made that space considerations and esthetic redressal necessitated extraction of the lateral incisors and mesiodens. The treatment plan was finalized with consent of patient after showing him the diagnostic wax up and explaining to him the required extractions. The patient subsequently underwent extraction of the mesiodens and teeth 12 and 22, elective endodontic treatment of teeth 13 and 11 as extensive preparation was required for these teeth for esthetic achievement, and mandatory endodontic treatment of exposed 21 with step back method (Fig. 3 and 4). On subsequent visit, tooth 21 was built up with a glass fibre post to increase core retention and a composite resin core. Teeth 13, 11, 21 and 23 were then prepared in conformation with the mock preparation done on the cast using putty indices. Temporisation was achieved after doing gingival retraction and making impressions in addition silicone material. Two 3-unit porcelain fused to metal fixed partial dentures were fabricated, giving stress to design of the lingual contours as per the guidance scheme developed on the articulator, and then seated after satisfactory coping trial and shade matching had been performed, to replace missing teeth 12 and 22 using teeth 13 and 11, and 21 and 23 as abutments respectively (Fig. 5). A cast removable partial denture was given to restore missing teeth 37, 36, 46, 47 and 48 incorporating Kennedy Class I design considerations including indirect retention and functional impression techniques. Patient responded well and was satisfied by the comprehensive treatment carried out by experts of various disciplines and is under active follow up.

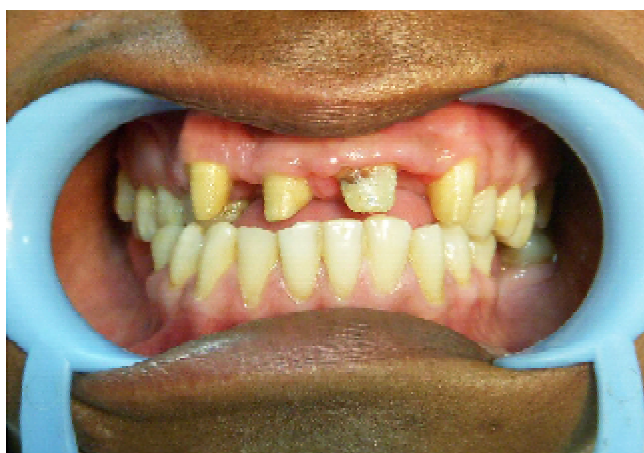

Figure 3: Intraoperative view of prepared abutments

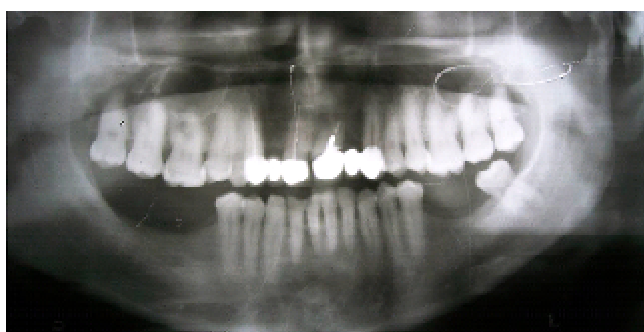

Figure 4: Post-operative OPG

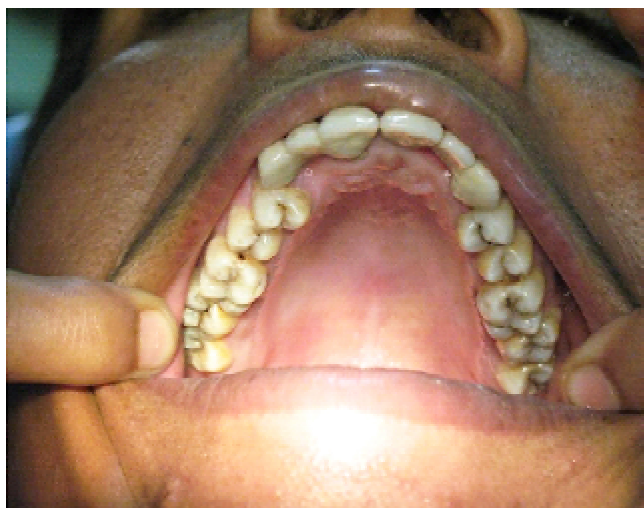


Figure 5: Post-operative occlusal view

DISCUSSION

The objective of the treatment was to ensure esthetic renovation in a patient with mesiodens, malalignment and fused teeth within limits and demands of the patient. Although the etiology of supernumerary teeth is not known, hyperdontia should be considered as multifactorial inheritance disorder¹⁶ and genetic factors influence its occurrence.¹⁷ With

familial aggregation, mesiodens is considered to be an autosomal dominant condition with incomplete penetrance.³ Widely accepted hyperactive theory implies that supernumerary teeth are the result of excessive but organised growth of the dental lamina.¹⁴

Fused teeth arise through union of two normally separated tooth germs, and depending upon the stage of development of the teeth at the time of union, the fusion may be either complete or incomplete, where even two independent pulp chambers and root canals may be seen. Whereas in gemination two teeth develop from one tooth bud and, as a result, the patient has a larger tooth but a normal (or increased) number, in fusion the patient would appear to be missing one tooth^{2,18-21}. Some degree of confusion can occur over the classification of gemination and fusion, albeit attempts to distinguish differences between them may have no clinical relevance. However, fusion may also be the union of a normal tooth bud to a supernumerary tooth germ.²² Also, normal intraoral and extraoral radiographs usually are not sufficient to establish a proper diagnosis.²³ In the present case report, as no tooth was found missing and another mesiodens was present on the right side, we therefore assumed that the condition could be classified as per Mader's two-tooth rule²⁴ as a case of complete fusion (the tooth had a single root canal and pulp chamber), where the tooth buds of the maxillary left central incisor and the maxillary left mesiodens had fused.^{21,22,24} The presence of the supernumerary teeth was the cause of the palatal placement of the maxillary right lateral and central incisor and left lateral incisor, as well as the labial drifting of the canines because of lack of space for proper eruption.¹⁴

Although the patient could have been managed less aggressively with orthodontic intervention, the lengthy time span required, precluded orthodontic treatment for the patient, who was about to get married. The decision of extracting both maxillary lateral incisors was taken after much deliberation as they were too far lingually placed to bring them into acceptable arch form without orthodontic intervention.²⁵ Their removal also aided in "unlocking" the mandible into freedom in protrusive guidance, which had been lost due to the maxillary laterals being 50-60% in cross bite.²⁶ Probably, this would also help in averting any future problems caused by the deranged occlusion. Elective endodontics was required on maxillary right central incisor and maxillary right canine as it was possible to bring them in an esthetic contour only through extensive tooth preparation.

Preparation of the teeth and fabrication of the crowns was a demanding process constantly requiring comparison with the putty indices and took several appointments, as the retainer for the left upper central incisor had to be brought to an approximately similar size and shape to that of the 5 mm thinner right central incisor, along with restoring symmetry of the incisal mid line to the facial midline. Use of optical illusions

had also to be made to make the thinner tooth look wider and vice versa.²⁷ Though satisfactory esthetic results were achieved, the long term prognosis of the prosthesis would be heavily dependent on the patient's oral hygiene maintenance.

Thus a logical, systematic careful multidisciplinary approach is important and should be undertaken whenever there is such an anomalous indication in order to achieve esthetically satisfactory results.

REFERENCES

1. Spear FM, Kokich VG, Mathews DP. Interdisciplinary management of anterior dental esthetics. *J Am Dent Assoc* 2006; 137: 160-9.
2. Rajendran R. Developmental disturbances of oral and paraoral structures. In: Shafer's Textbook of Oral Pathology. Rajendran R, Sivapathasundharam B (eds). 5th ed, Elsevier, 2007, 65.
3. Russell KA, Folwarczna MA. Mesiodens- diagnosis and management of a common supernumerary tooth. *J Can Dent Assoc* 2003; 69: 362-6.
4. Stellzig A, Basdra EK, Komposch G. Mesiodentes: incidence, morphology, etiology. *J Orofacial Orthopedics* 1977; 58: 144-53.
5. Ravn JJ. Aplasia, supernumary teeth and fused teeth in the primary dentition: an epidemiologic study. *Scand J Dent Res* 1971; 79:1-6.
6. Luten JR Jr. The prevalence of supernumary teeth in primary and mixed dentitions. *J Dent Child* 1967; 34: 346-53.
7. Sedano HO, Gorlin RJ. Familial occurrence of mesiodens. *Oral Sur Oral Med Oral Pathol* 1969; 27: 360-1.
8. Castaldi CR, Bodnarchuk A, MacRae PD, Zacherl WA. Incidence of congenital anomalies in permanent teeth of a group of Canadian children aged 6-9. *J Can Dent Assoc (Tor)* 1966; 32: 154-9.
9. Tay F, Pang A, Yuen S. Unerupted maxillary supernumary teeth: report of 204 cases. *ASDC J Dent Child* 1984; 51: 289-94.
10. Hurlen B, Humerfelt D. Characteristics of premaxillary hyperdontia, a radiographic study. *Acta Odontol Scand* 1985; 43: 75-81.
11. Zilberman Y, Malron M, Shteyer A. Assessment of 100 children in Jerusalem with supernumerary teeth in the premaxillary region. *ASDC J Dent Child* 1992; 59: 44-7.
12. Huang W, Tsai T, Su HL. Mesiodens in the primary dentition stage: a radiographic study. *ASDC J Dent Child* 1992; 59: 186-9.
13. Osuji OO, Paedodont D, Hardie J. Dental anomalies in a population of Saudi Arabian children in Tabuk. *Saudi Dent J* 2002; 14: 11-4.
14. DePasquale S, Azzopardi A, Camilleri S. Mesiodens preventing eruption of a permanent central incisor. *Malta Medical J* 2005; 17: 37-9.
15. Rosenthaler H, Quinn PD, Rose LF. Surgical-orthodontic management of an unerupted maxillary incisor. *J Am Dent Assoc* 1979; 98: 731-3.
16. Weber F. Supernumerary teeth. *Dent Clin North Am* 1964; 509-17.
17. Scheiner MA, Sampson WJ. Supernumerary teeth: a review of literature and four case reports. *Aust Dent J* 1997; 42: 160-5.
18. , Martens LC, De Craene LG. A complete fusion in the primary human dentition: a histological approach. *ASDC J Dent Child* 1988; 55: 362-7.
19. Velasco LF, de Araujo FB, Ferreira ES, Velasco LE. Esthetic and functional treatment of a fused permanent tooth: a case report. *Quintessence Int* 1997; 28: 677-80.
20. de Siqueira VC, Braga TL, Martins MA, Ratz R, Martins MD. Dental fusion and dens evaginatus in the permanent dentition: literature review and clinical case report with conservative treatment. *J Dent Child (Chic)* 2004; 1: 69-72.
21. Danesh G, Schrijnemakers T, Lippold C, Schäfer E. A fused maxillary central incisor with dens evaginatus as a talon cusp. *Angle Orthod* 2007; 77: 176-80.
22. Blaney TD, Hartwell GR, Bellizzi R. Endodontic management of a fused tooth: a case report. *J Endod* 1982; 8: 227-30.
23. Mader CL. Fusion of teeth. *J Am Dent Assoc* 1979; 98: 62-4.
24. Mupparapu M, Singer SR, Goodchild JH. Dens evaginatus and dens invaginatus in a maxillary lateral incisor: report of a rare occurrence and review of literature. *Aust Dent J* 2004; 49: 201-3.
25. Claman L, Alfaro MA, Mercado A. An interdisciplinary approach for improved esthetic results in the anterior maxilla. *J Prosthet Dent* 2003; 89: 1-5.
26. Palmer RM, Palmer PJ, Newton JT. Dealing with esthetic demands in the anterior maxilla. *Periodontol* 2000 2003; 33: 105-18.
27. Heinlein WD. Anterior teeth: Esthetics and function. *J Prosthet Dent* 1980; 44: 389-93.