

# Management of a mid-root Horizontal fracture using Ni-Ti file and MTA based sealer: Two year follow-up

Rhythm Bains<sup>1</sup>, Pranab Mishra,<sup>2</sup> Kapil Loomba<sup>3</sup> and Anju Loomba<sup>4</sup>

## ABSTRACT

Traumatic injuries of the face often result in tooth crown fracture, root fracture or even complete loss of tooth. Root fractures result due to sudden impact on the teeth, often separating it into an apical and coronal fragment. Immediate treatment involves rigid stabilisation of fractured tooth and intra-radicular reinforcement if required. Prognosis depends on site of fracture, age of the patient, maturity of root and time elapsed between trauma and treatment.

**Keywords:** Intra-radicular stabilisation, root fracture, rigid stabilisation.

## INTRODUCTION

Maxillofacial trauma results in fractures of facial bones, soft tissue injuries and fractures of crown or roots of teeth or even loss of teeth (avulsion). Root fractures result due to a sudden forceful impact on the teeth, often resulting in separation of root into an apical and coronal fragment. The maxillary central incisors are most commonly affected (68%), followed by maxillary lateral (27%) and mandibular



Dr. Rhythm Bains completed her graduation (BDS) from Government Dental College & Hospital, Patiala (Pb), in year 2001 and postgraduation (MDS) in Conservative Dentistry & Endodontics from King George's Medical University, Lucknow in 2008. Currently, she is working as Assistant Professor in Faculty of Dental Sciences, King George's Medical University, Lucknow (UP), India.

Department of Conservative Dentistry & Endodontics, <sup>1</sup>Faculty of Dental Sciences, King George's Medical University, <sup>3</sup>Career Post Graduate Institute of Dental Sciences & Hospital, <sup>4</sup>Private Practitioner, Dental Care Clinic, Lucknow, <sup>2</sup>Private Practitioner, Aastha Dental Clinic, Sambalpur, Odisha.

### Address for Correspondence:

Dr. Rhythm Bains, Department of Conservative Dentistry & Endodontics, Faculty of Dental Sciences, King George's Medical University, Lucknow (UP)-226003, India.

Contact: +91 9935033439,

E-mail: dochrhythm77@gmail.com

Date of Submission : 07-07-2014

Reviews Completed : 11-08-2014

Date of Acceptance : 20-08-2014

incisors (5%). These injuries are relatively uncommon among all dental traumas, with an overall incidence of 0.5-7% in permanent teeth.<sup>1</sup> Fracture can occur in the cervical, middle or apical third of roots, and those of middle-third are most common. The prognosis of fractured tooth depends on many factors like age of the patient, maturity of root formation; time elapsed between trauma and treatment, site of fracture and approximation of the fractured fragments. Fractures in the cervical 1/3rd have a guarded prognosis, while those in middle and apical third have a better prognosis.<sup>2,3</sup> The immediate treatment involves splinting and stabilization of the fractured root and is successful in approximately 80% cases with middle and apical root fractures. Endodontic treatment may be required in cases with irreversible pulpitis, necrosis or when considerable time has elapsed between treatment and trauma.<sup>4,5</sup> Reinforcement of the tooth is desirable in such cases, and use of stainless steel files, metal posts and fibre posts has been documented to stabilise the fractured root.

Mineral Trioxide aggregate (MTA) has been used multifariously in endodontics especially in cases where regeneration of cemental tissues is required, as perforation repair and root end filling.<sup>6</sup> MTA has also been used successfully in cases of root fractures, apexification, apexogenesis and reinforcing structurally weakened teeth having compromised radicular dentin thickness.<sup>7</sup> Recently, MTA based root canal sealer (Fillapex, Angelus) has been introduced which has advantages like better handling, faster setting and good sealing ability. The present case report discusses the treatment and two year follow-up of mid-third root fracture of a central incisor using intra radicular stabilisation using a sterilized rotary file and MTA based sealer, followed by a permanent crown splint.

## CASE REPORT

A 25 year old, non-smoker, healthy male patient reported to the Endodontics Department, with the chief complaint of mobile upper anterior tooth. Clinical examination revealed a mobile 21 (maxillary left central incisor). Radiographic examination showed a mid root fracture in 21 [Type I, Div.2 (B), Loomba *et al.*] (Fig.1).<sup>3</sup> The patient gave a history of traumatic injury to the tooth a few weeks back. Pulp

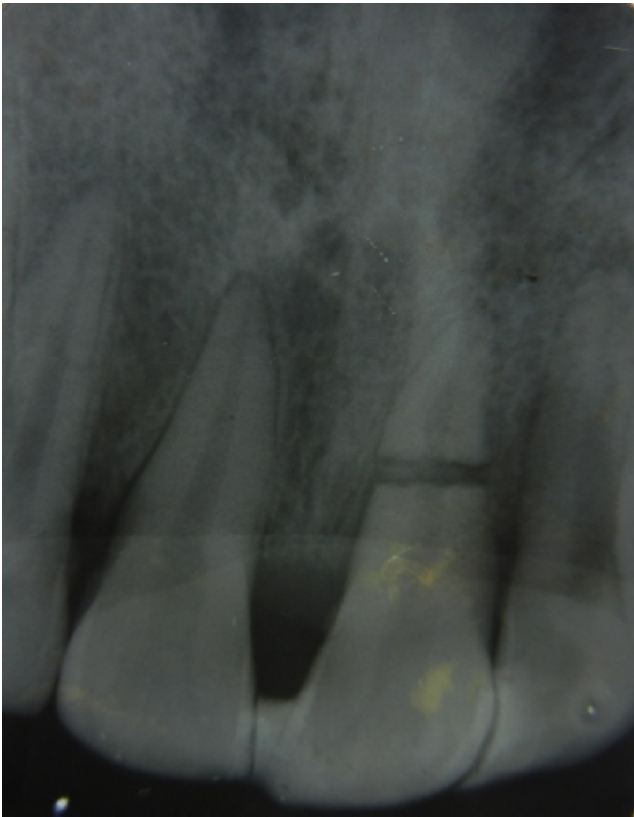


Figure 1: IOPA showing mid-root fracture in 21

sensitivity test was performed for tooth 11 and 21 using electric pulp tester (Parkell). Both the teeth showed delayed response compared to the healthy teeth. The immediate treatment was rigid splinting of the fractured tooth with an orthodontic wire splint and composite resin from canine to canine. After local anaesthesia and rubber dam application, access cavity was prepared with an Endoaccess bur (Dentsply, Maillefer) in both the central incisors. For tooth 11, the mid-root fracture segment was bypassed with the help of # 20 K-file (Fig. 2). The working length was determined electronically, and the canal was prepared with Protaper (Dentsply, Maillefer) hand files till size F2 in tooth 11 and till # 50 K-files in 21. During the instrumentation, canals were irrigated with normal saline and 2% Chlorhexidine. Non-setting calcium hydroxide paste (Metapex, META) was given as intracanal medicament and access cavity was sealed with a non-eugenol cement (Cavit, 3M, ESPE). In the subsequent appointment, 11 was obturated using guttapercha and AH-plus sealer (Dentsply, Maillefer). For the tooth 21, it was decided to use an MTA based sealer (Fillapex, Angelus) and a sterilised F1 file, cut upto the working length as an obturating material, to provide rigidity to the root. Size 10 silver points were used as accessory cones. The butt end of the file and accessory cones were reduced with a wheel shaped diamond, and the access cavity was filled with high strength glass ionomer cement (Fuji IX,

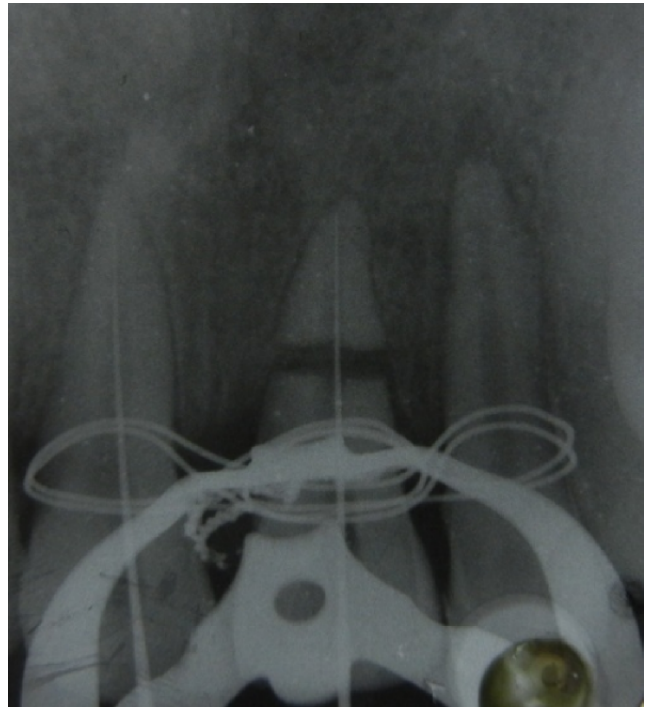

Figure 2: Fractured fragments by-passed with a K-file.

GC, Tokyo) (Fig. 3). The wire splint was replaced by a fibre splint Interlig, Haeger) and bonded from canine to canine. After a 3 month follow up, joint metal ceramic crowns were

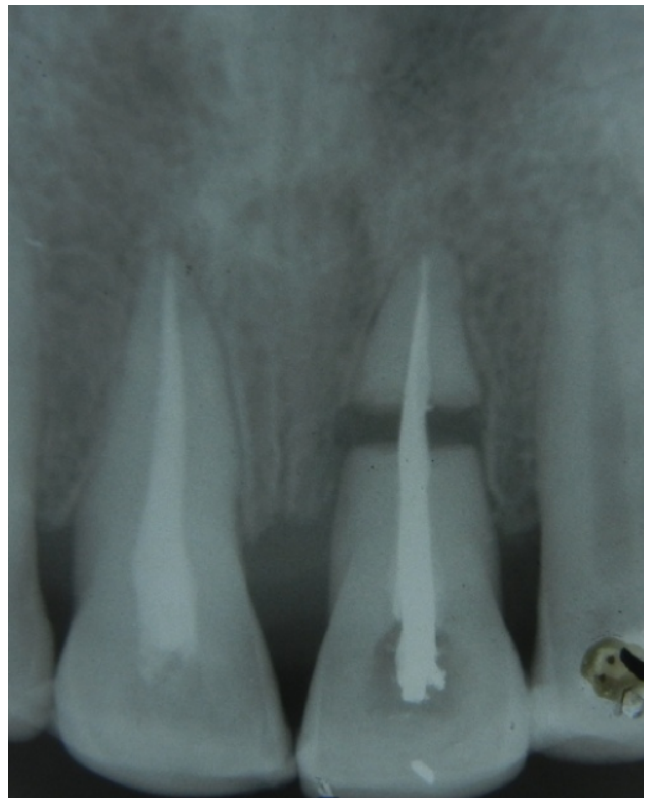


Figure 3: Tooth 21 obturated with Protaper file and accessory silver cones.

given as a permanent splint in 11 and 21 (Fig. 4). Two-years after the treatment, patient was asymptomatic, and did not report any mobility or tenderness on percussion. Also, radiographic healing was evident as there was rounding of margins at the fractured ends and no untoward periapical changes had occurred (Fig.5).

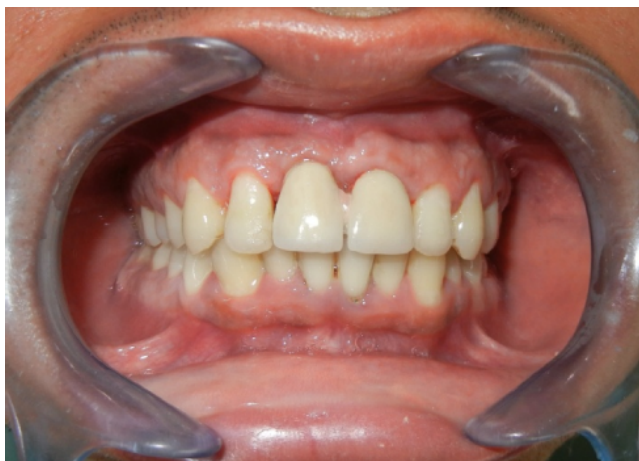

Figure 4: Joint metal ceramic crown in relation to 11,21.

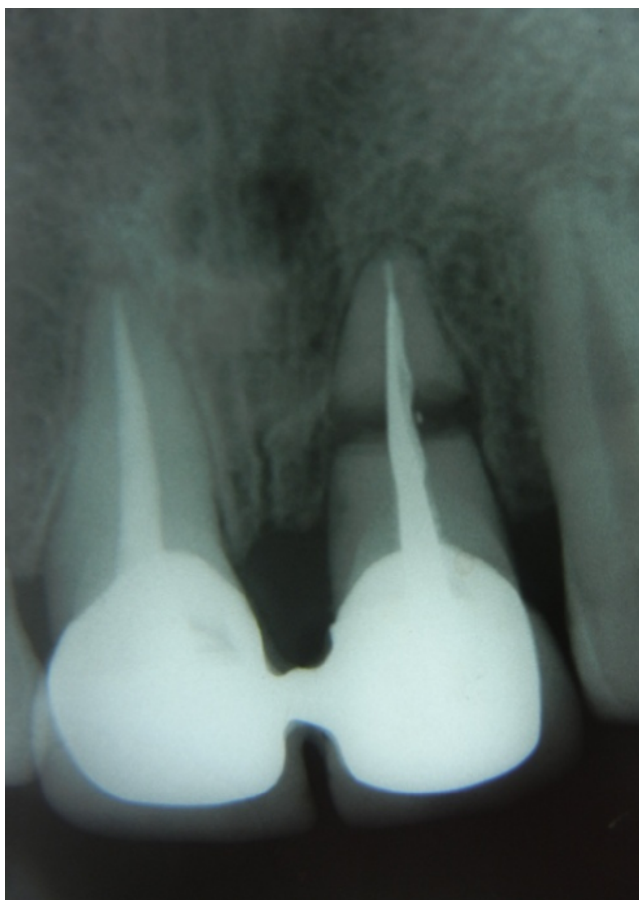

Figure 5: Two year follow-up radiograph.

## DISCUSSION

Various types of histological responses seen at the fracture line in the roots can be categorised into four types: type I, interposition of calcified tissue (callus formation, radiographically fractured fragments appear in close contact); type II, interposition of connective tissue, (peripheral rounding of the fracture's ends visible); type III, interposition of bone and connective tissue, (appears on a radiograph as a clear separation between fractured ends); and type IV, the interposition of granulation tissue, caused by an infected or necrotic pulp.<sup>8</sup> The type of tissue response varies with the degree of trauma, and Type II is amongst the most common outcome reported in cases with successful outcomes.<sup>1,9</sup>

The treatment plan and prognosis depends largely on the site of fracture, age of the patient, pulpal status, time elapsed between trauma and treatment and mobility of the coronal segment. In cases of fractures in the apical third, spontaneous healing has been reported even without any treatment.<sup>10</sup> Endodontic treatment, if required can be limited to the coronal segment in such cases as the apical pulp is mostly vital.<sup>11</sup> Cases where the fracture line is in the cervical one-third of the root and there is luxation of the coronal segment, immediate treatment of choice is rigid stabilisation of the tooth for few weeks, followed by intra radicular stabilisation of the root. In the present case, the fracture line was in the middle of the root, and a considerable time had elapsed between trauma and his dental visit, so immediate rigid stabilisation was performed and endodontic therapy was planned to improve the prognosis. Intraradicular stabilization of fractured roots using rigid materials like stainless steel H-files, metallic posts or silver points have been reported in older literature also.<sup>12,13</sup> Here, Nickel titanium (Ni-Ti) rotary file was used to reinforce the root as Ni-Ti is a biocompatible alloy, does not corrode in oral atmosphere and has a modulus of elasticity and flexural properties better than stainless steel.

MTA has been used in the past to strengthen weakened roots and has shown to have excellent biocompatibility, is cementogenic, good sealing and antimicrobial properties and ability to set in the presence of blood. The newly introduced MTA based sealer MTA Fillapex has good flow characteristics and overcomes one major disadvantage of MTA, i.e. poor handling characteristics. Thus, it serves as a good sealing material in fracture sites where both root reinforcement and cementogenesis are desirable.<sup>14,15</sup>

## CONCLUSION

The present case report shows good clinical and radiological healing over the two year follow-up period. Considering the present scenario where dental implants are fast replacing

endodontic treatment procedures, it can be said that all teeth which have a hope to be saved by endodontic treatment should be taken up for treatment to preserve the natural proprioception and function of the roots.

## REFERENCES

1. Wölner-Hanssen AB, von Arx T. Permanent teeth with horizontal root fractures after dental trauma. A retrospective study. *Schweiz Monatsschr Zahnmed* 2010; 120: 200-5.
2. Herweijer JA, Torabinejad M, Bakland LK. Healing of horizontal root fractures. *J Endod* 1992; 18: 118-22.
3. Loomba K, Bains R, loomba A, Bains VK. A proposal for classification of tooth fractures based on treatment need *J Oral Sci* 2010; 52: 517-29.
4. Ferrari PHP, Zaragoza RA, Ferreira LE, Bombana AC. Horizontal Root Fractures: A case report. *Dental Traumatol* 2006; 22: 215-7.
5. Oikarinen K, Andreasen JO, Andreasen FM. Rigidity of various fixation methods used as dental splints. *Dental Traumatol* 1992; 8: 113-9.
6. Bains R, Bains VK, Loomba K, Verma K, Nasir A. Management of pulpal floor perforation and grade II Furcation involvement using mineral trioxide aggregate and platelet rich fibrin: A clinical report. *Contemp Clin Dent* 2012; 3: s224-7.
7. Altinok B, Kargul B. Use of Mineral Trioxide Aggregate in Permanent Incisors with Horizontal Root Fractures: A Five-Year Follow-Up. *OHDMBSC* 2010; IX: 224-28.
8. Andreasen FM, Andreasen JO, Cvek M. Root fractures. In: Andreasen J O, Andreasen F M, Andersson L (Ed.): *Textbook and color atlas of traumatic injuries to the teeth*. Munksgaard, Kopenhagen 2007: 337-1.
9. Jacobsen I, Zachrisson BU. Repair characteristics of root-fractures in permanent anterior teeth. *Scand J Dent Res* 1975; 83: 355-64.
10. Ozbek M, Serper A, Calt S. Repair of untreated horizontal root fracture: A case report. *Dental Traumatol* 2003; 19: 296-7.
11. Görduysus M, Avcu N, Görduysus O. Spontaneously healed root fractures: two case reports. *Dent Traumatol* 2008; 24:115-6.
12. Subay RK, Subay MO, Yilmaz B, Kayatas M. Intraradicular splinting of a horizontally fractured central incisor: a case report. *Dent Traumatol* 2008; 24: 680-84.
13. Parekh DJ, Sathyanarayanan R, Manjunath MT. Clinical management of mid-root fracture in maxillary central incisors: case reports. *Int J Oral Sci* 2010; 2: 215-21.
14. Lee SJ, Monsef M, Torabinejad M. Sealing ability of a mineral trioxide aggregate for repair of lateral root perforations. *J Endod* 1993;19: 541-4.
15. Hachmeister DR, Schindler WG, Walker WA, Thomas DD. The sealing ability and retention characteristics of mineral trioxide aggregate in a model of apexification. *J Endod* 2002; 28: 386-90.