

Transfiguration of Smile by Anterior Tooth Replacement through Remodeling of Hard and Soft Tissue Profile with Adjunct to Implant Osseointegration

Abstract

The treatment choice for the recovery of missing teeth has been expanded for two patients and clinicians with the utilization of dental implants. For the success of dental implants, the quality and the amount of the available bone and soft tissues in the recipient site are very important factors. However, because of the tumor, injury, periodontal ailment, and so on, these variables might be undermined or inaccessible which again brings out the need for extra hard and soft tissue manipulation. This paper outlines a technique using a modified rolled palatal pedicle connective tissue graft with an autogenous bone graft from the mandibular symphysis area to achieve a predictable long-term success of dental implants prosthesis.

Keywords: Bone grafts, emergence profile, soft tissue thickness

Introduction

Substitution of missing maxillary front tooth with lingering edge imperfection is a test and hard assignment to accomplish. Esthetics outcome relies upon three-dimensional emergence profiles of the prosthesis, tooth shape, and shade of fixed prosthesis. The emergence profile is reliant on remaining alveolar ridge volume, width, and length. A careful treatment planning is obligatory for the accomplishment of the objective of an anticipated esthetic outcome for anterior ridge defects.^[1]

Tooth loss along with it brings inescapable sequelae of quick resorption of the alveolar bone because of the absence of intraosseous incitement by periodontal ligament (PDL) fibers and renders to the deficient amount of bone, following tooth loss.^[2]

Tooth loss in the anterior maxilla causes early bone resorption, however, essentially in the horizontal direction, and mostly loss of bone occurs on the buccal side (Att *et al.*, 2009).^[3] There is a high incidence (91%) of residual ridge remodeling after anterior tooth loss. Most of these are class III deformities (Siebert's characterization).^[4]

As reported in the literature, implant treatment is a productive, profitable, and

This is an open access journal, and articles are distributed under the terms of the Creative Commons Attribution-NonCommercial-ShareAlike 4.0 License, which allows others to remix, tweak, and build upon the work non-commercially, as long as appropriate credit is given and the new creations are licensed under the identical terms.

For reprints contact: WKHLRPMedknow_reprints@wolterskluwer.com

predictable choice for the restoration of missing teeth.^[5] Along with teeth, the strength of delicate soft tissue around implants is an important factor to accomplish an acceptable esthetic outcome.^[6]

A nutritive undersupply of the bone may happen because of deficient peri-implant tissues bringing about fixture loss because of resorption. Appropriate gingival architecture is particularly significant so as to accomplish attractive anterior esthetics.^[7] For augmentation of defects, bone can be harvested from nonessential bones, such as from iliac crest, mandibular symphysis (chin area), and anterior mandibular ramus (coronoid process).^[2]

The present case report demonstrates a technique using a modified rolled palatal pedicle connective tissue graft, with an autogenous bone graft from mandibular symphysis area to correct the localized maxillary anterior alveolar ridge defects while replacing an anterior missing tooth using implant therapy.

Case Report

A systemically healthy patient aged 20 years reported to the department of prosthodontics with the chief complaint of a missing tooth and a discolored tooth in the

How to cite this article: Chopra D, Bhaumik K, Mishra SK. Transfiguration of smile by anterior tooth replacement through remodeling of hard and soft tissue profile with adjunct to implant osseointegration. *Contemp Clin Dent* 2022;13:95-9.

**Devendra Chopra,
Kaushitaki
Bhaumik,
Sumit Kumar
Mishra**

*Department of Prosthodontics
and Crown and Bridge,
Saraswati Dental College
and Hospital, Lucknow,
Uttar Pradesh, India*

Submitted : 05-Oct-2020
Revised : 18-Jan-2021
Accepted : 15-Apr-2021
Published : 23-Mar-2022

Address for correspondence:

*Dr. Devendra Chopra,
Vivek Khand 4/72, Gomti Nagar,
Lucknow, Uttar Pradesh, India.
E-mail: drdevendra45@gmail.com*

Access this article online

Website:
www.contempclindent.org

DOI: 10.4103/ccd.ccd_870_20

Quick Response Code:



maxillary anterior region. On clinical examination, it was found that the patient had a congenitally missing maxillary right central incisor. The patient was motivated to replace his congenitally missing maxillary right central incisor via orthodontic and prosthodontic treatment. However, due to financial constraints, patients insisted on replacement of clinically missing maxillary right lateral incisor only. Intraoral and radiographic examination revealed a severe alveolar ridge deformity in relation to missing maxillary right lateral incisor region [Figure 1a] and a root canal-treated maxillary left central incisor. Cone-beam computed tomography scan [Figure 1b] of the maxillary anterior region showed thin remaining bone (Siebert's class III defect), and clinical examination showed thin gingival biotype (>1.5) with a narrow band of attached gingiva. The region needs to be augmented through hard and soft tissue augmentation.

Among all the options, the patient opted for autologous bone grafting followed by implant placement for the missing tooth and PFM crown for the central incisor, and informed consent was obtained from the patient.

After administration of local anesthesia, incisions are made and mucoperiosteal flap was raised to expose the surgical site. An acrylic surgical stent was placed in the patient's mouth for easy access. The implant site preparation was completed at a depth of 10.5 mm [Figure 1c].

A narrow platform implant with a diameter of 3 mm and a length of 10 mm is inserted. Final insertion was done using a torque ratchet with an insertion torque of 30 Ncm [Figure 1d].

In the attached gingiva, a midline vertical release incision [Figure 2a] was performed to get access to the donor site extending from distal sides of both the canines. Particulate bone graft material was taken from mandibular symphysis region [Figure 2b] and compacted on the defect

site [Figure 2c]. The site was covered with a biodegradable membrane.

A partial-thickness horizontal incision [Figure 2d] was made on the palatal aspect of the ridge from central incisor to canine. From the horizontal incision line, an oblique incision was placed from mesial line angle of right canine to second premolar [Figure 3a]. Underlying connective tissue was exposed. Parallel incision was given from the mesial line angle of the central incisor. These parallel incisions were joined by a horizontal incision at the apical end. A full-thickness palatal connective tissue pedicle graft approximately two times more than the apicocoronal length of the ridge defect was rolled onto the defect site. Horizontal mattress sutures were placed on the donor and defect site [Figure 3b and c]. A prefabricated Essex appliance made of vacuum-formed sheet and artificial lateral incisor [Figure 3d] was inserted in the patient's mouth.

Three-month postoperative evaluation showed a considerable amount of ridge thickness with soft tissue emergence profile [Figure 4a], with no postoperative complications which have been assessed with a periapical radiograph [Figure 4b]. A second-stage surgery was performed after 6 months for exposure of the permucosal element and placement of a healing abutment to recontour the emergence profile [Figure 4c]. After 10 days, a provisional crown [Figure 4d] was given. The adjacent root canal-treated central incisor was prepared for porcelain fused to metal crown, and simultaneously, the titanium abutment was milled and adjusted for the lateral incisor [Figure 5a]. Impression was obtained from an open tray method [Figure 5b]. After metal coping trial [Figure 5c], final prosthesis was delivered with desirable esthetics and accurate fit [Figure 5d].

Discussion

Dental implants are the treatment of choice for the restoration of missing teeth these days. However, the

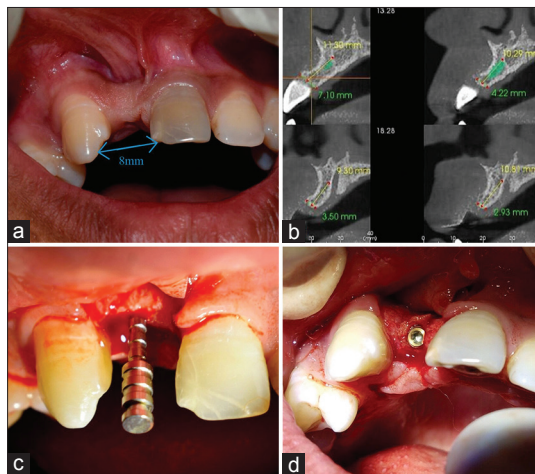


Figure 1: (a) Missing maxillary right lateral incisor region. (b) Cone-beam computed tomography scan. (c) Evaluation with paralleling depth pins. (d) Final insertion

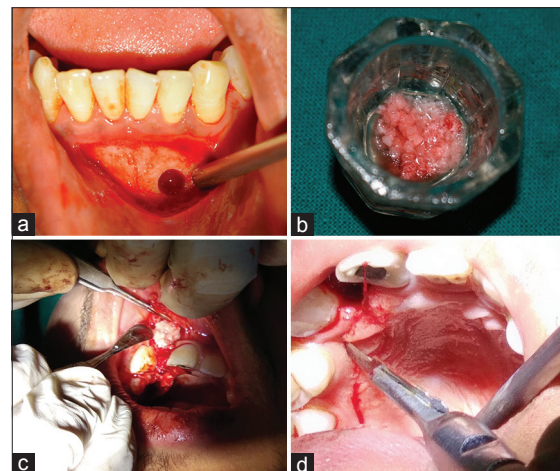


Figure 2: (a) Midline vertical incision. (b) Particulate bone graft. (c) Compaction on the defect site. (d) Partial thickness horizontal incision

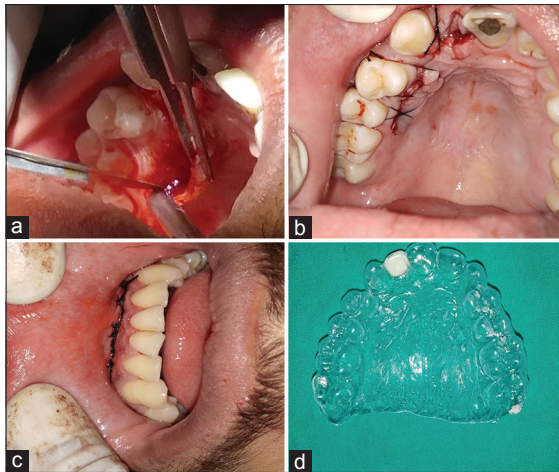


Figure 3: (a) Oblique incision from mesial line angle extending from right canine to second premolar. (b and c) Placement of horizontal mattress sutures. (d) Essex appliance

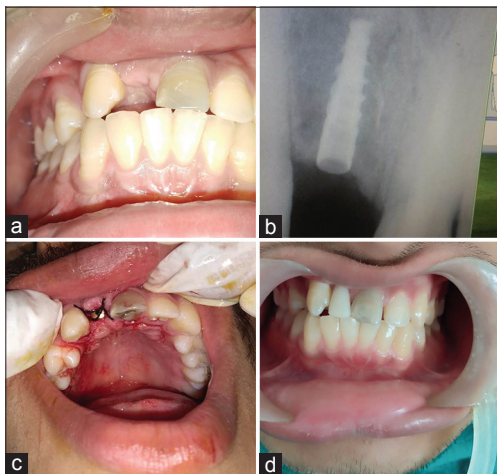

Figure 4: (a) Postoperative evaluation after six months of healing. (b) Periapical radiograph 12 region. (c) Placement of healing abutment. (d) Provisional crown

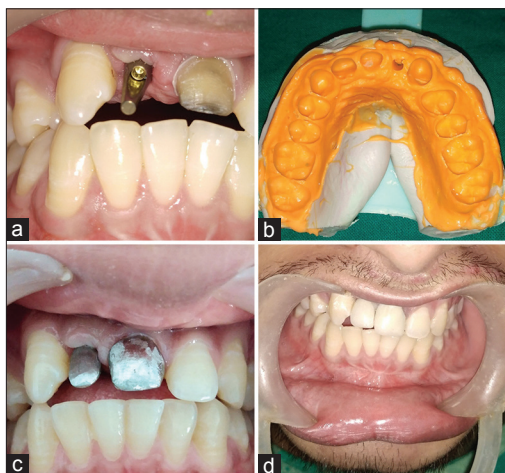

Figure 5: (a) Milling of titanium abutment and preparation of adjacent central incisor. (b) Final impression. (c) Metal coping trial. (d) Final prostheses

placement of an implant in the alveolar bone stays a difficult factor for the vast majority of the clinicians

because of resorption of the alveolar ridge bringing about an absence of bone volume.^[1]

The placement of esthetic implants is motivated by both the theory of restoration and biology. To place the implant esthetically, it should fulfill the criteria of contour so that the restoration is gratifying. It should be positioned biologically to allow both hard and soft tissue architecture to be preserved. In the current case report, implant was placed 3–4 mm apical to the gingival margin of the contra lateral tooth to enable a natural emergence profile of restoration. Mesiodistal placement was also considered by maintaining a space of 1.5–2 mm with the adjacent tooth.^[8]

Different soft and hard tissue manipulation strategies were suggested for the management of alveolar deformities. Methodology for hard tissue improvement includes autologous block grafts, bone grafts, and substitutes^[5] and guided bone regeneration.^[9] To achieve an adequate emergence profile, it is necessary to have an ample amount of bone and soft tissue thickness, especially on the buccal side.

Techniques for soft tissue profile improvement include onlay free mucosal graft interpositional connective tissue grafts, pouch graft, roll pedicle grafts, and modified roll pedicle grafts.^[1] In the current trend, these roll grafts are a viable treatment alternative to achieve a desirable soft tissue contour. The advantage of using palatal pedicle connective tissue is due to its intact blood supply which reduces the risk of graft necrosis and provides proper bulk of soft tissue.^[1]

For appropriate esthetic result, deficient alveolar bone height and width regularly require bone manipulation procedures performed either previously, at the time of, or after the implant surgical procedure.^[10] The best quality level of bone grafting materials is autografts. These are taken from a same patient, acquired from one site and placed in another site, and regenerate the bone by the procedure of osteogenesis and osteoinduction. Using xenografts could elicit acute and chronic immune reactions, as well as disease transmission due to interaction of residual proteins within graft particles and the host cell receptors.^[10] The comfort of autograft bone material is that the bone structures, for example, minerals, collagen, and viable osteoblasts, and bone morphogenic proteins, are kept up. It is osteoinductive, biocompatible, simple to control, and effortlessly profited from remote destinations. When compared to other alternatives, transplants of autogenous origin have a shorter healing and incorporation period. The symphysis region had been selected for harvesting in this clinical situation to cover the defect due to the presence of denser bone. Placement of healing cap over the implant helps augment the gingiva, resulting in excellent emergence profile, gingival, and papilla contour.

In this new combined surgical and prosthetic approach for correcting soft tissue dehiscence and hard tissue defect,

there is also a placement of short clinical crown, so it should not induce any stress on the underlying healing soft tissue. However, within 2–3 months of healing, all the marginal gingival tissue and mesial and distal papilla grip the provisional crown, resulting in a proper emergence profile. It also ensures the increase vascular supply and allows the tissue to occupy the proximal space adjacent to the definitive prostheses.

Declaration of patient consent

The authors certify that they have obtained all appropriate patient consent forms. In the form the patient(s) has/have given his/her/their consent for his/her/their images and other clinical information to be reported in the journal. The patients understand that their names and initials will not be published and due efforts will be made to conceal their identity, but anonymity cannot be guaranteed.

Acknowledgment

The authors want to thank Dr. Vivek Bains, Professor and HOD, Department of Periodontics, Saraswati Dental College, Lucknow, for his clinical assistance in the grafting.

Financial support and sponsorship

Nil.

Conflicts of interest

There are no conflicts of interest.

References

1. Reddy PK, Bolla V, Koppolu P, Srujan P. Long palatal connective tissue rolled pedicle graft with demineralized freeze-dried bone allograft plus platelet-rich fibrin combination: A novel technique for ridge augmentation-Three case reports. *J Indian Soc Periodontol* 2015;19:227-31.
2. Kumar P, Vinitha B, Fathima G. Bone grafts in dentistry. *J Pharm Bioallied Sci* 2013;5:S125-7.
3. Bernhard P, Werner Z, Georg W, Richard P. To Graft or not to Graft? EVIDENCE-BASED GUIDE to Decision Making in Oral Bone Graft Surgery; 2012.
4. Khojasteh A, Esmaeelinejad M, Aghdashi F. Regenerative Techniques in Oral and Maxillofacial Bone Grafting, A Textbook of Advanced Oral and Maxillofacial Surgery Volume 2, Mohammad Hosein Kalantar Motamedi, IntechOpen; 2015.
5. Adell R, Lekholm U, Rockler B, Brånemark PI. A 15-year study of osseointegrated implants in the treatment of the edentulous jaw. *Int J Oral Surg* 1981;10:387-416.
6. Mazzotti C, Stefanini M, Felice P, Bentivogli V, Mounssif I, Zucchelli G. Soft-tissue dehiscence coverage at peri-implant sites. *Periodontol 2000* 2018;77:256-72.
7. Weber HP, Cochran DL. The soft tissue response to osseointegrated dental implants. *J Prosthet Dent* 1998;79:79-89.
8. Jivraj S, Chee W. Treatment planning of implants in the aesthetic zone. *Br Dent J* 2006;201:77-89.
9. Anderson LE, Inglehart MR, El-Kholy K, Eber R, Wang HL. Implant associated soft tissue defects in the anterior maxilla: A randomized control trial comparing subepithelial connective tissue graft and acellular dermal matrix allograft. *Implant Dent* 2014;23:416-25.
10. Mittal Y, Jindal G, Garg S. Bone manipulation procedures in dental implants. *Indian J Dent* 2016;7:86-94.